

CORRECTION

Open Access



# Correction to: Different aspects of Alzheimer's disease-related amyloid $\beta$ -peptide pathology and their relationship to amyloid positron emission tomography imaging and dementia

Dietmar Rudolf Thal<sup>1,2,3,4\*</sup>, Alicja Ronisz<sup>1,3</sup>, Thomas Tousseyn<sup>1,2</sup>, Ajeet Rijal Upadhaya<sup>4</sup>, Karthikeyan Balakrishnan<sup>4,5</sup>, Rik Vandenberghe<sup>3,6,7</sup>, Mathieu Vandenbulcke<sup>3,6,8</sup>, Christine A. F. von Arnim<sup>9,10</sup>, Markus Otto<sup>9</sup>, Thomas G. Beach<sup>11</sup>, Johan Lilja<sup>12</sup>, Kerstin Heurling<sup>13</sup>, Aruna Chakrabarty<sup>14</sup>, Azzam Ismail<sup>14</sup>, Christopher Buckley<sup>15</sup>, Adrian P. L. Smith<sup>15</sup>, Sathish Kumar<sup>16</sup>, Gill Farrar<sup>15</sup> and Jochen Walter<sup>16</sup>

**Correction to: *Acta Neuropathol Commun* 7, 178 (2019)**  
<https://doi.org/10.1186/s40478-019-0837-9>

In the publication of the original article [1], Fig. 5f had an incorrect diagram.

The original figure shows in panel F the diagram: A $\beta$  Phase

The correct diagram for panel F is: CAA-stage

A $\beta$  Phase was already provided in Fig. 5b

The updated Fig. 5 is published in this correction article.

#### Author details

<sup>1</sup>Department of Imaging and Pathology, KU-Leuven, Leuven, Belgium. <sup>2</sup>Department of Pathology, UZ-Leuven, Leuven, Belgium. <sup>3</sup>Leuven Brain Institute, KU-Leuven, Leuven, Belgium. <sup>4</sup>Laboratory for Neuropathology – Institute of Pathology, University of Ulm, Ulm, Germany. <sup>5</sup>Department of Gene Therapy, University of Ulm, Ulm, Germany. <sup>6</sup>Department of Neurosciences, KU-Leuven, Herestraat 49, 3000 Leuven, Belgium. <sup>7</sup>Department of Neurology, UZ-Leuven, Leuven, Belgium. <sup>8</sup>Department of Geriatric Psychiatry, UZ-Leuven, Leuven, Belgium. <sup>9</sup>Department of Neurology, University of Ulm, Ulm, Germany. <sup>10</sup>Department of Geriatrics, University Medical Center Göttingen, Göttingen, Germany. <sup>11</sup>Civin Laboratory for Neuropathology, Banner Sun Health Research Institute, Sun City, AZ, USA.

<sup>12</sup>Hermes Medical Solutions AB, Stockholm, Sweden. <sup>13</sup>Department of Psychiatry and Neurochemistry, Wallenberg Centre for Molecular and Translational Medicine, University of Gothenburg, Gothenburg, Sweden. <sup>14</sup>Pathology and Tumour Biology, Leeds Institute of Molecular Medicine, St. James Hospital, Leeds, UK. <sup>15</sup>GE Healthcare Life Sciences, Amersham, UK. <sup>16</sup>Department of Neurology, University of Bonn, Bonn, Germany.

Published online: 03 August 2020

#### Reference

1. Thal DR, Ronisz A, Tousseyn T et al (2019) Different aspects of Alzheimer's disease-related amyloid  $\beta$ -peptide pathology and their relationship to amyloid positron emission tomography imaging and dementia. *Acta Neuropathol Commun* 7:178. <https://doi.org/10.1186/s40478-019-0837-9>

The original article can be found online at <https://doi.org/10.1186/s40478-019-0837-9>.

\* Correspondence: [Dietmar.Thal@kuleuven.be](mailto:Dietmar.Thal@kuleuven.be)

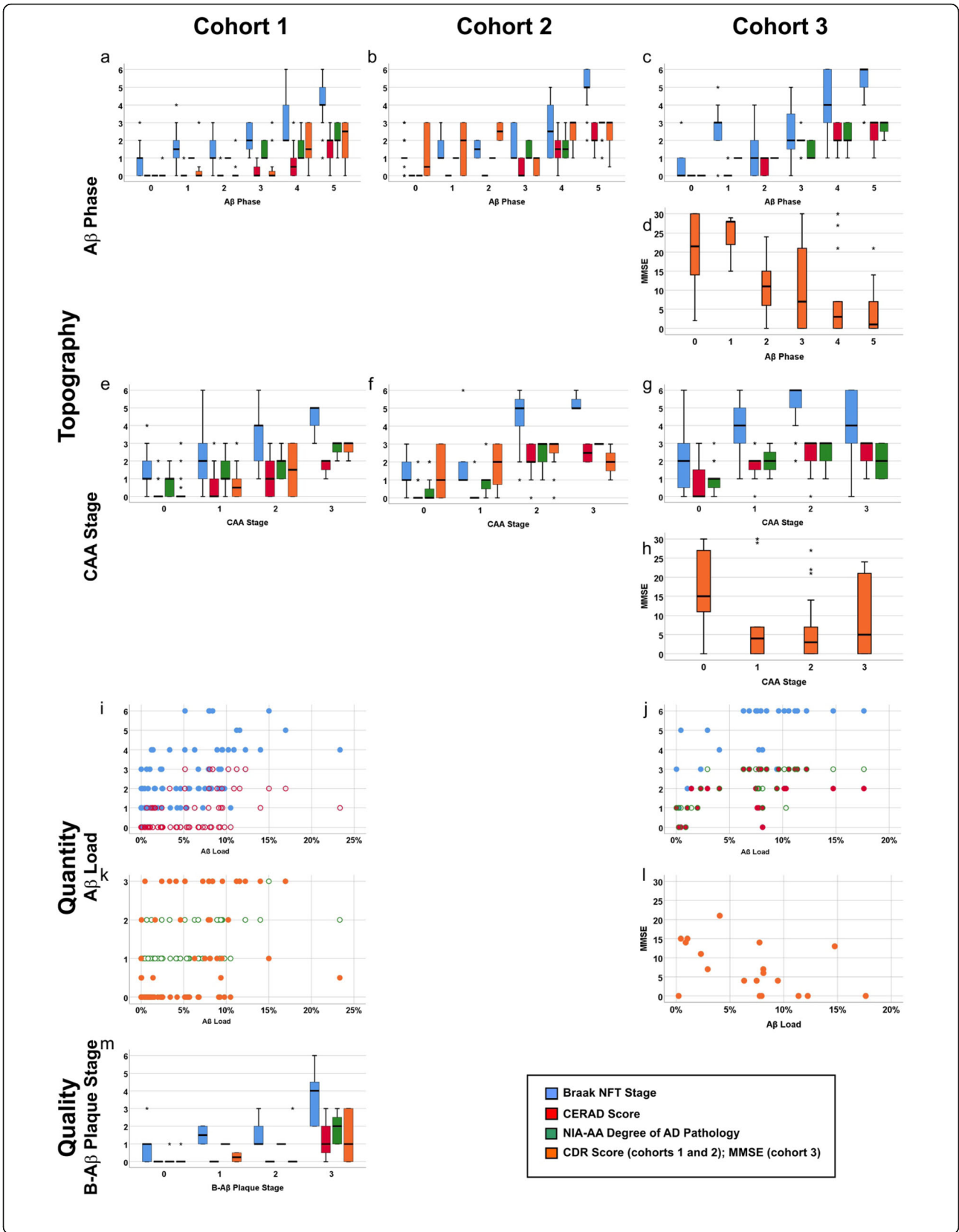
<sup>1</sup>Department of Imaging and Pathology, KU-Leuven, Leuven, Belgium

<sup>2</sup>Department of Pathology, UZ-Leuven, Leuven, Belgium

Full list of author information is available at the end of the article



© The Author(s). 2020 **Open Access** This article is licensed under a Creative Commons Attribution 4.0 International License, which permits use, sharing, adaptation, distribution and reproduction in any medium or format, as long as you give appropriate credit to the original author(s) and the source, provide a link to the Creative Commons licence, and indicate if changes were made. The images or other third party material in this article are included in the article's Creative Commons licence, unless indicated otherwise in a credit line to the material. If material is not included in the article's Creative Commons licence and your intended use is not permitted by statutory regulation or exceeds the permitted use, you will need to obtain permission directly from the copyright holder. To view a copy of this licence, visit <http://creativecommons.org/licenses/by/4.0/>. The Creative Commons Public Domain Dedication waiver (<http://creativecommons.org/publicdomain/zero/1.0/>) applies to the data made available in this article, unless otherwise stated in a credit line to the data.



**Fig. 5** Boxplot and scatter diagrams depicting the correlation of the Braak NFT stages, CERAD-scores for neuritic plaque pathology, NIA-AA scores of AD pathology, and the clinical dementia scores (CDR for cohorts 1 and 2 and MMSE for cohort 3) with the topographical A $\beta$  parameters A $\beta$  phase (**a-d**) and CAA stage (**e-h**), the quantitative measure of the A $\beta$  load (**i-l**), and the qualitative aspect provided by the B-A $\beta$  plaque stages (**m**). The boxplots are depicted separately for cohorts 1 (**a, e, i, k, m**), 2 (**b, f**), and 3 (**c, d, g, h, j, l**). The Braak NFT stages, CERAD scores, NIA-AA degrees of AD pathology, and CDR scores correlated with all parameters depicted here ( $r = 0.287\text{--}0.920$ ,  $p < 0.001$ ). Likewise, the MMSE scores showed a negative correlation with the A $\beta$  phase and the CAA stages in cohort 3 ( $r = -0.514\text{--}0.315$ ,  $p \leq 0.012$ ) except for the A $\beta$  load ( $p = 0.051$ ) which showed only a trend (for detailed statistical analysis see Additional file 1: Table S7)